



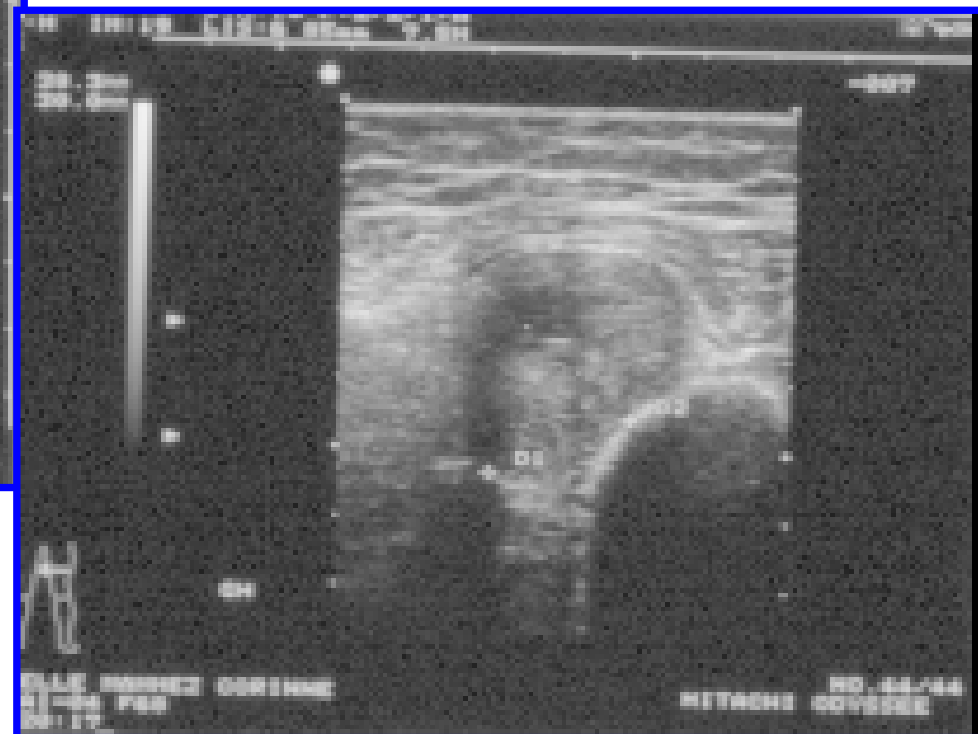
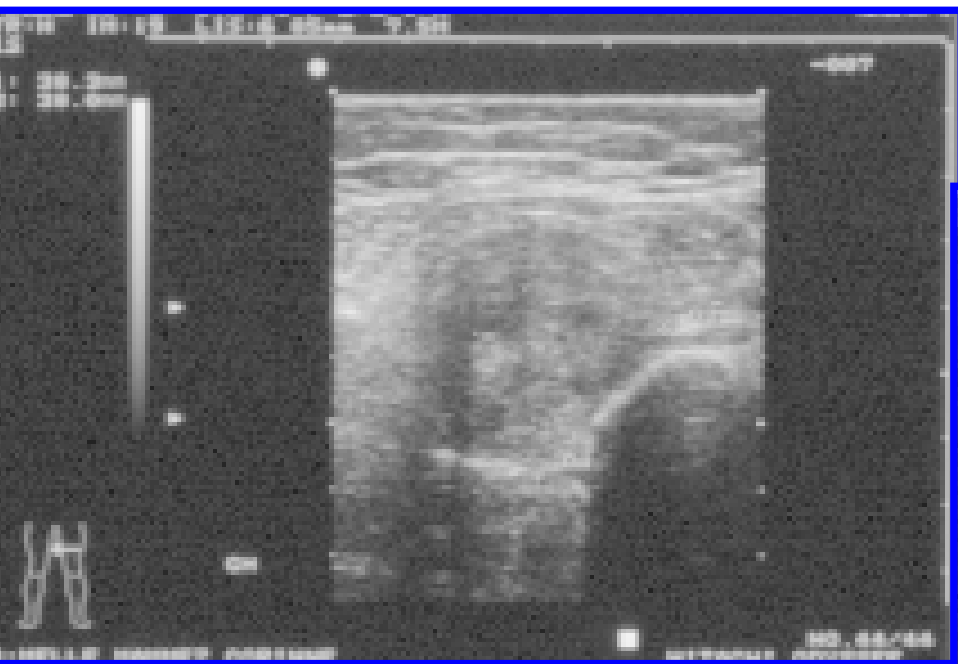
# Cas 2

## Cas 2: Corinne M...



- ⌘ Patiente de 38 ans, consultant pour une masse des parties molles
- ⌘ Pas d 'ATCD. Pas de traumatisme. Injections hormonales ss-cutanées (ttt de stérilité)
- ⌘ Tuméfaction indolente de cuisse Droite.
  - ☑ constatée en 12/03; pas d 'augmentation selon la patiente en 5 mois
  - ☑ échographie en 05.04 : tumeur de 7cm, profonde, intramusculaire

# Cas 2: Corinne M...

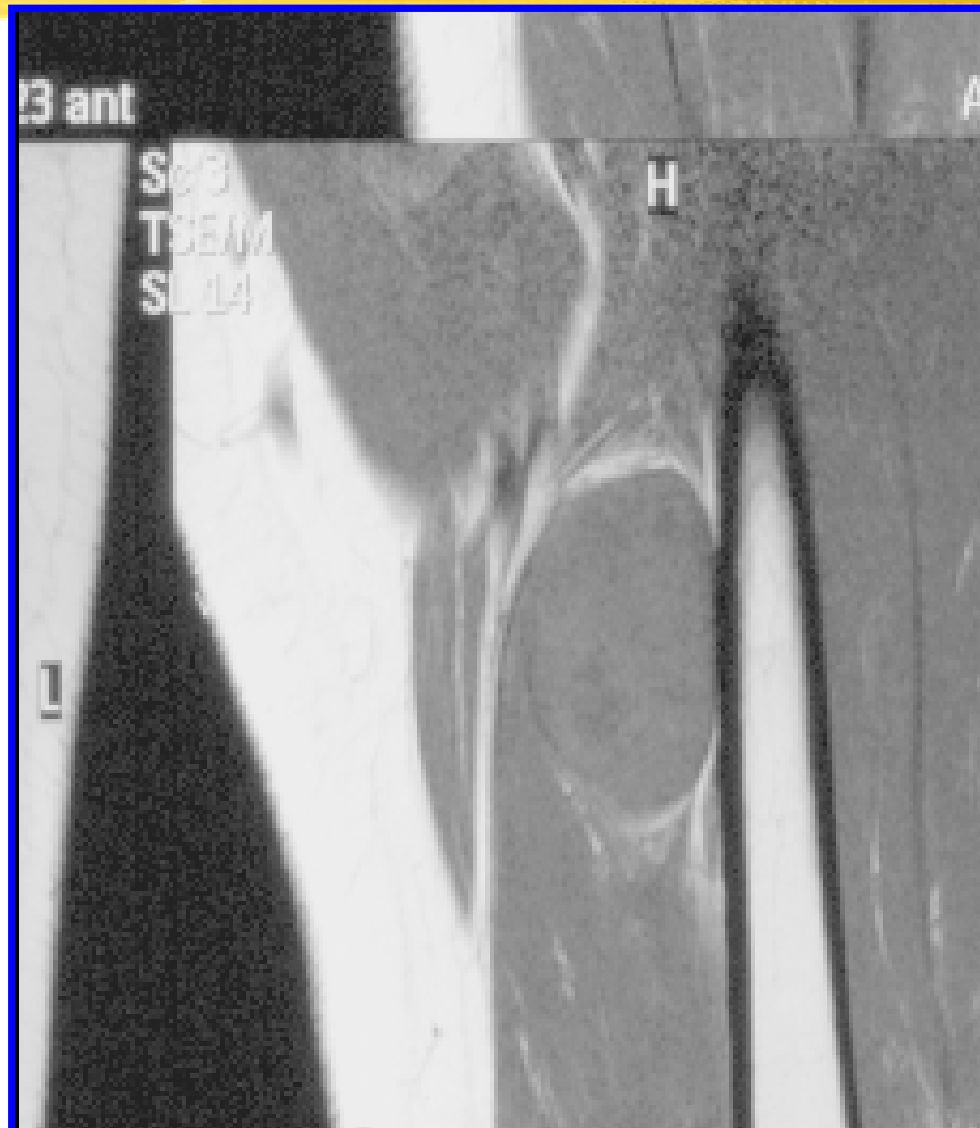


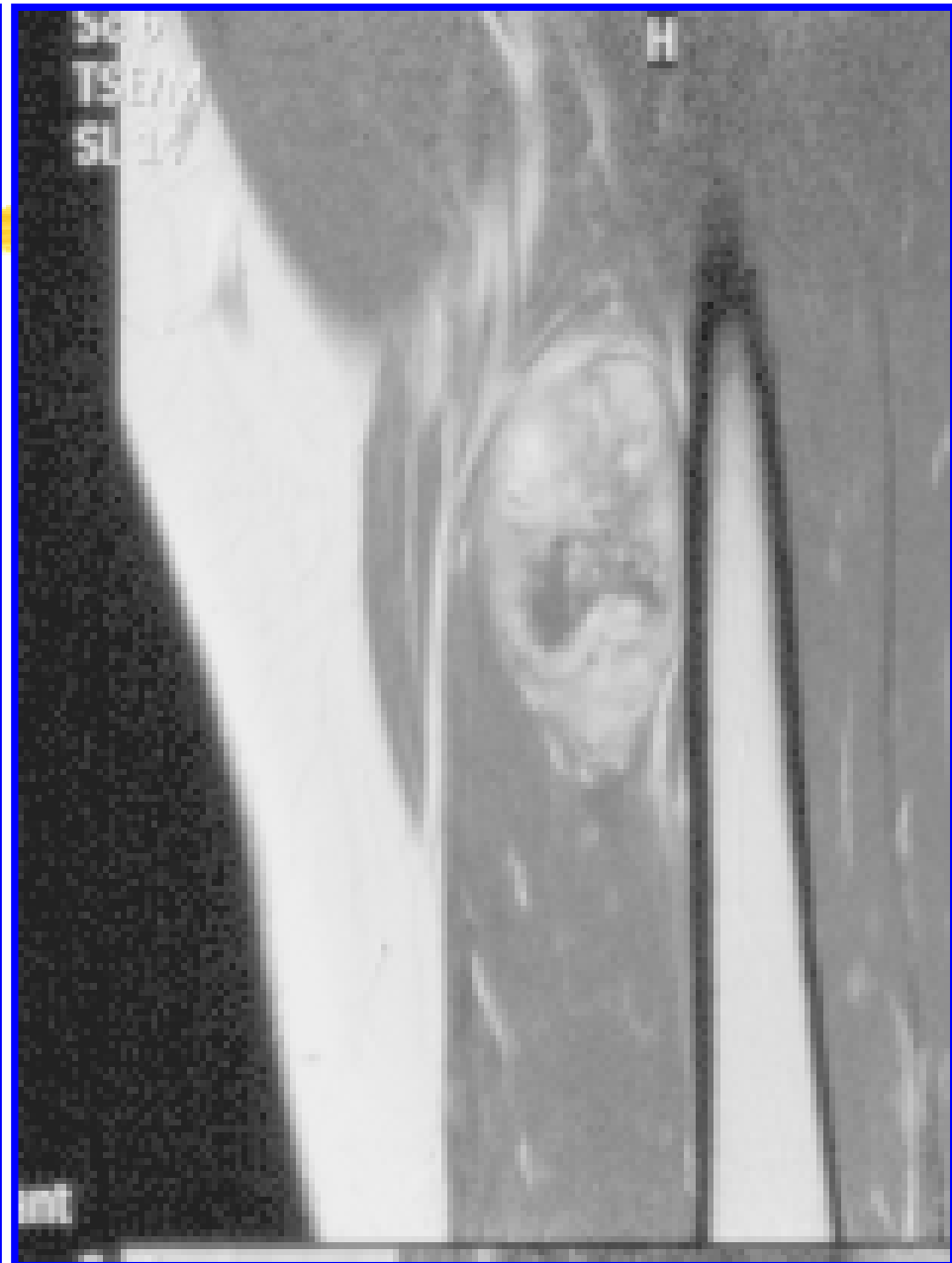
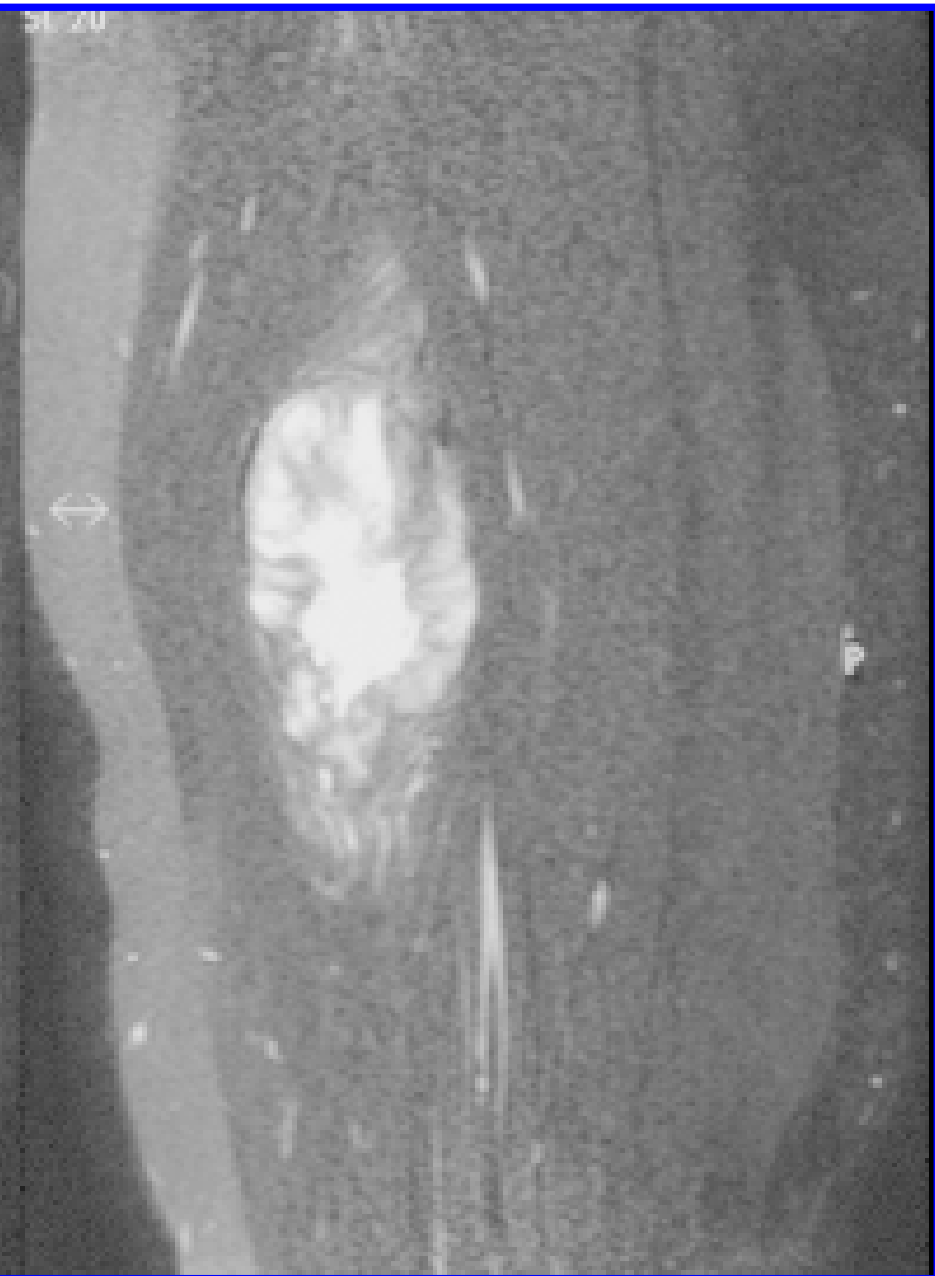
## Cas 2: Corinne M...



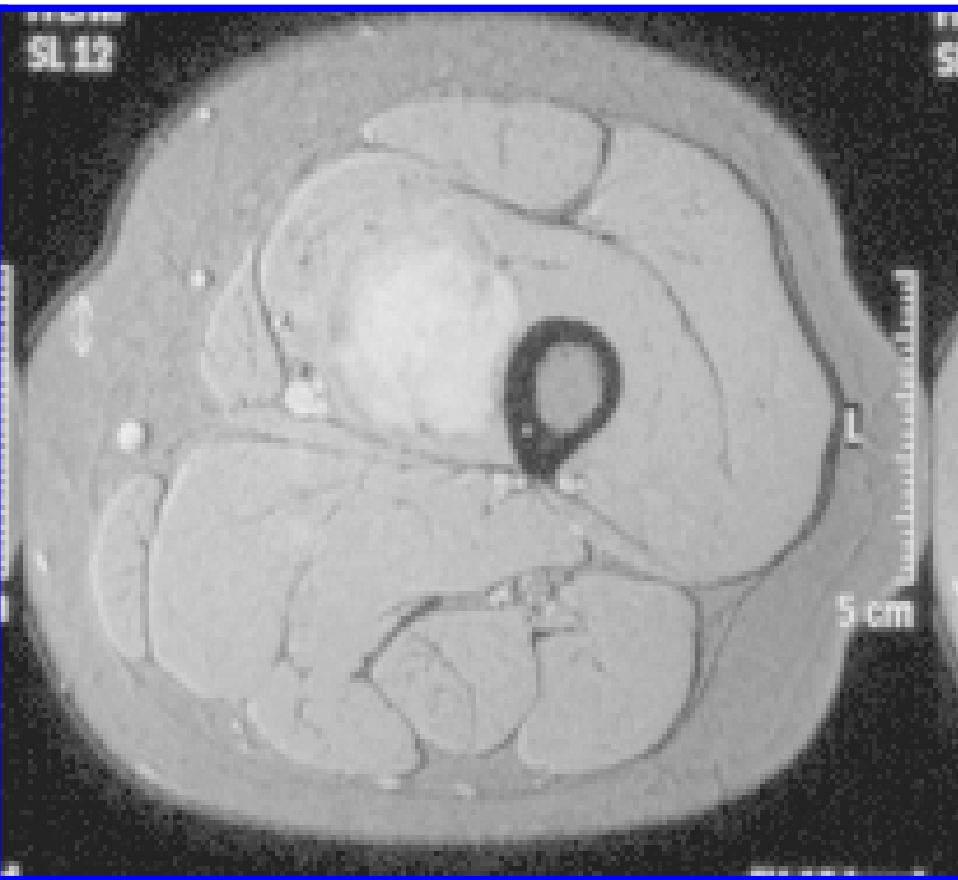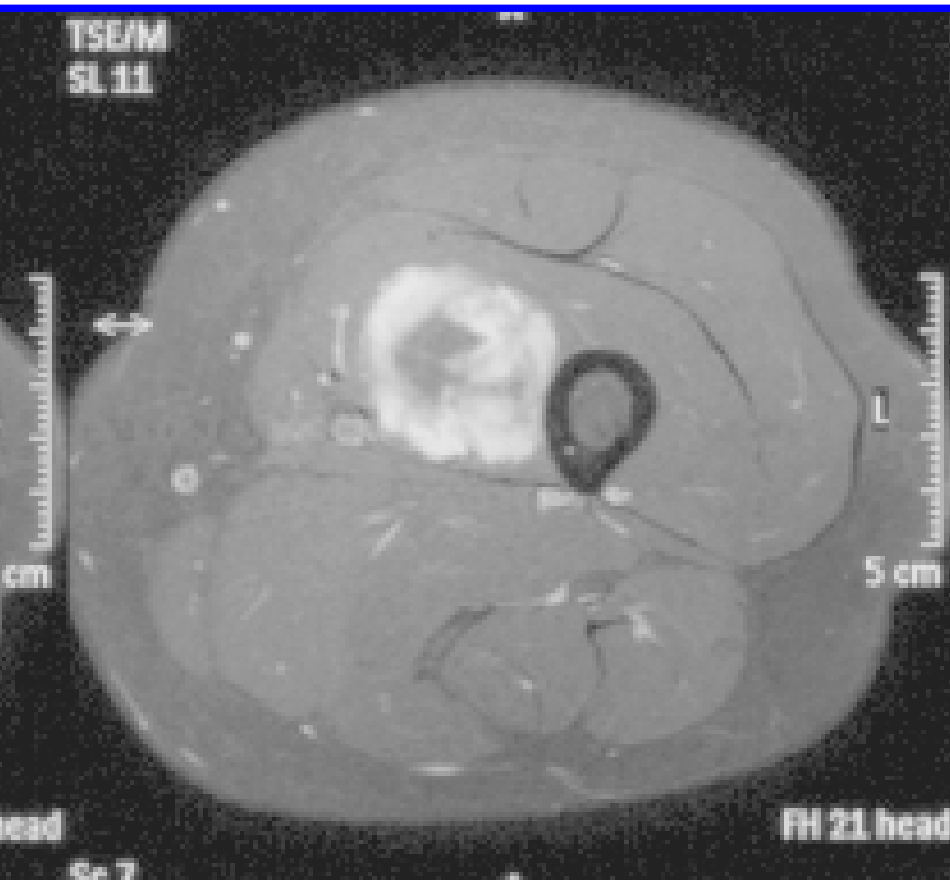
⌘ IRM 08/04, avant consultation, au CH de Pau  
puis à l'IB

## Cas 2: Corinne M...





# Cas 2: Corinne M...

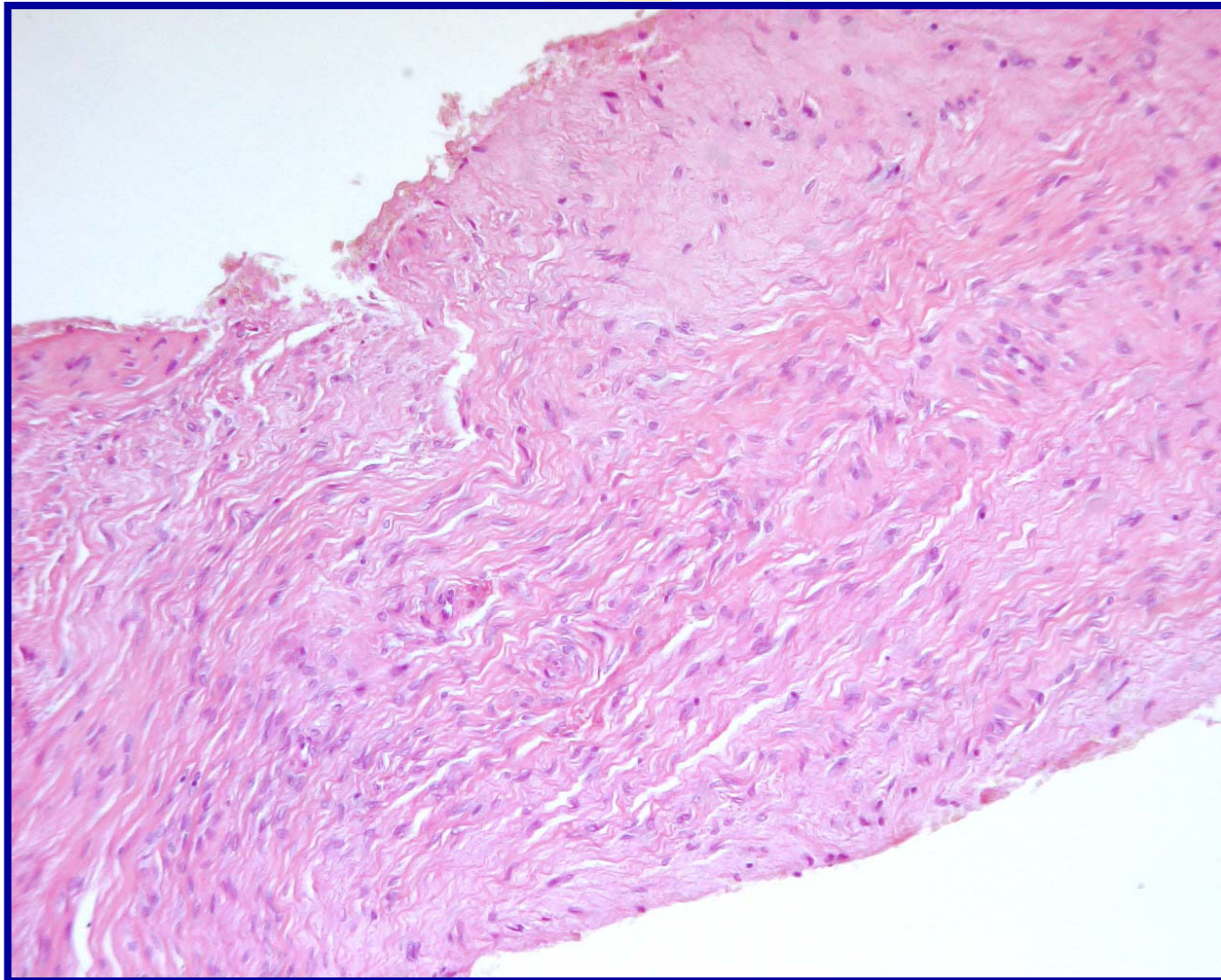


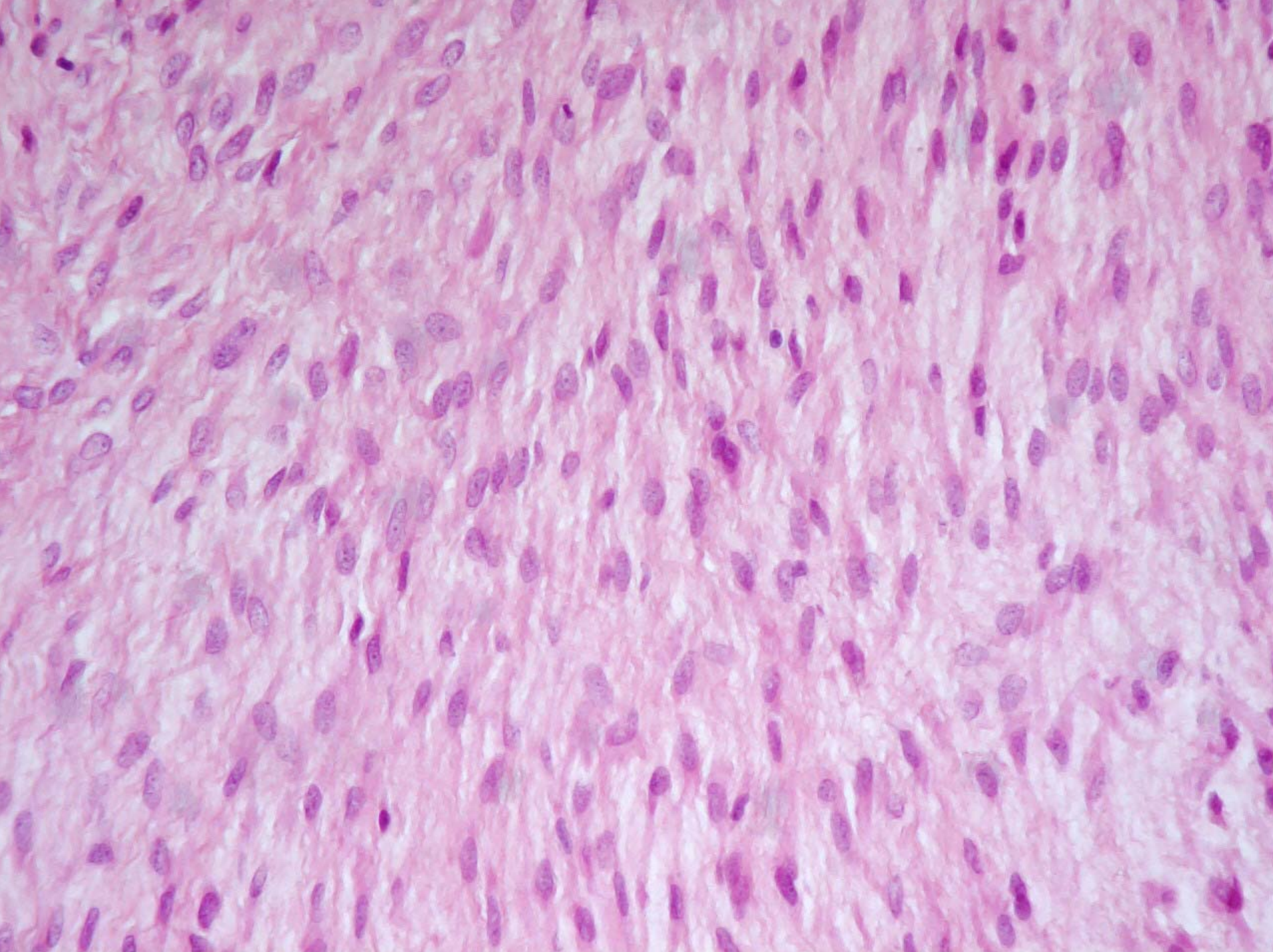
## **Cas 2: Corinne M...**



- ⌘ Existe-t-il une indication de biopsie?
- ⌘ Comment faire la biopsie?

## Cas 2: Microbiopsie sous écho



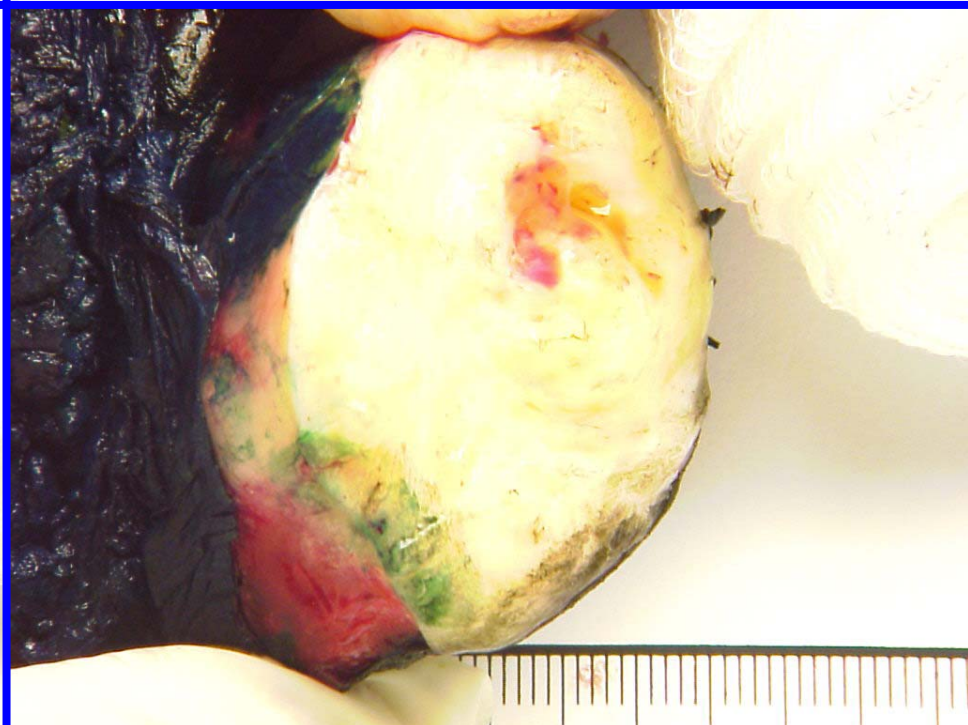


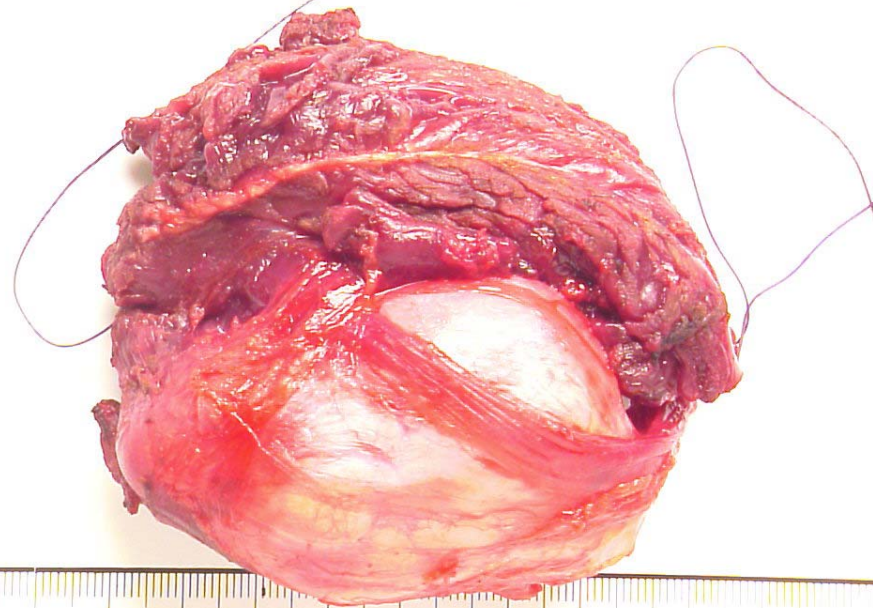


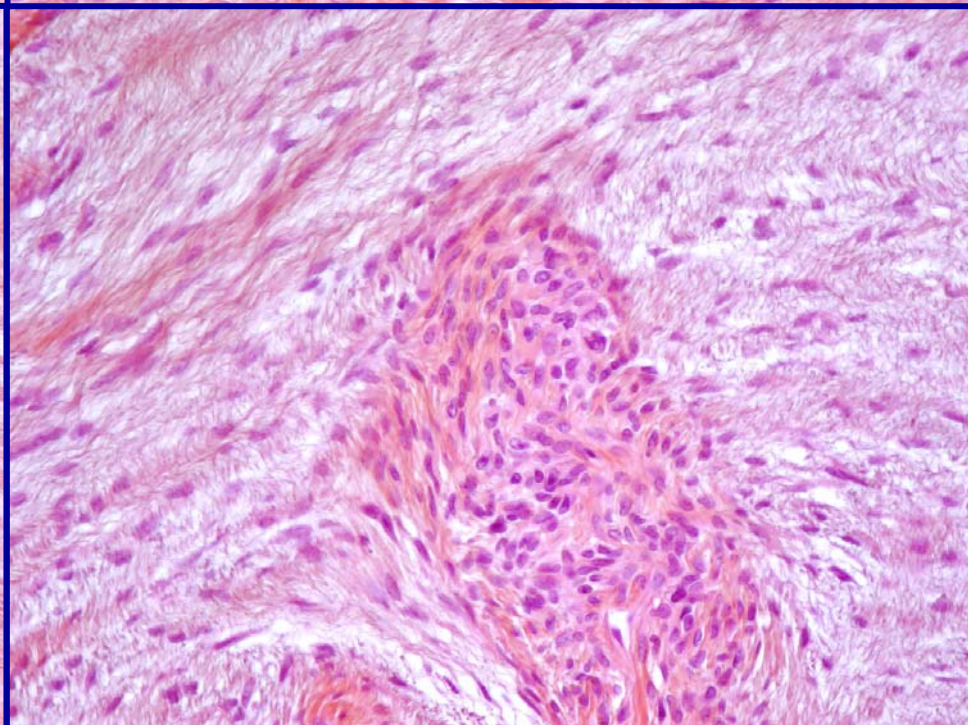
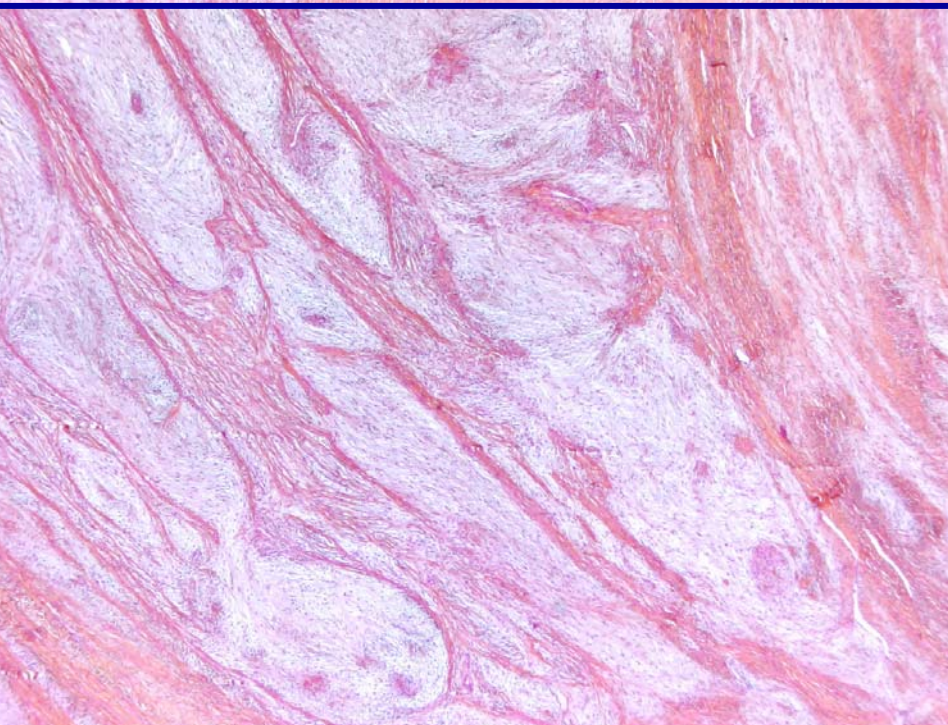
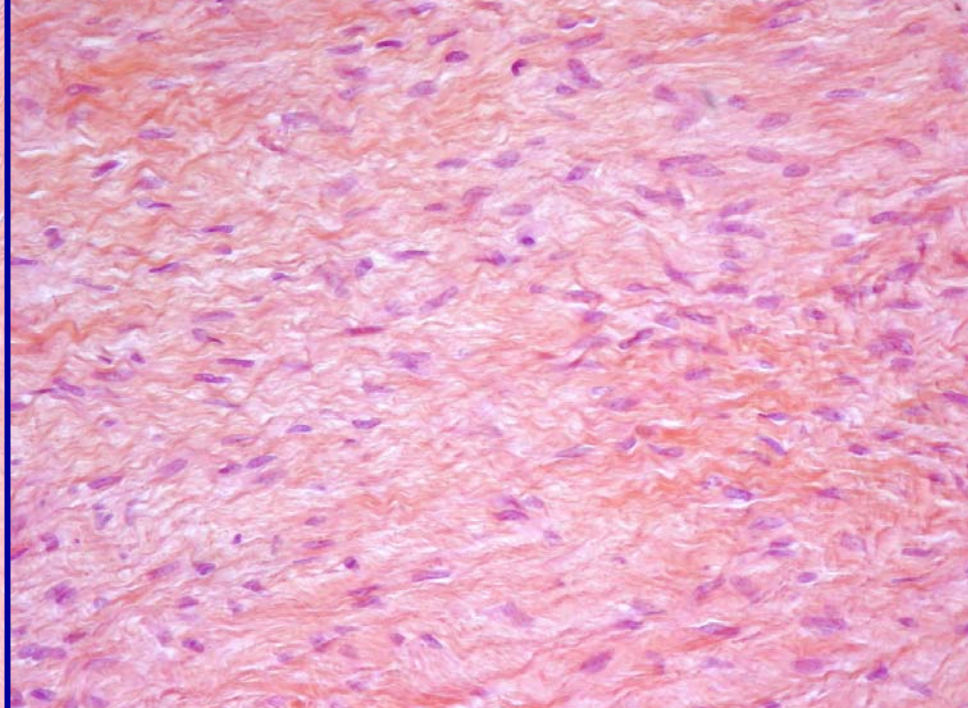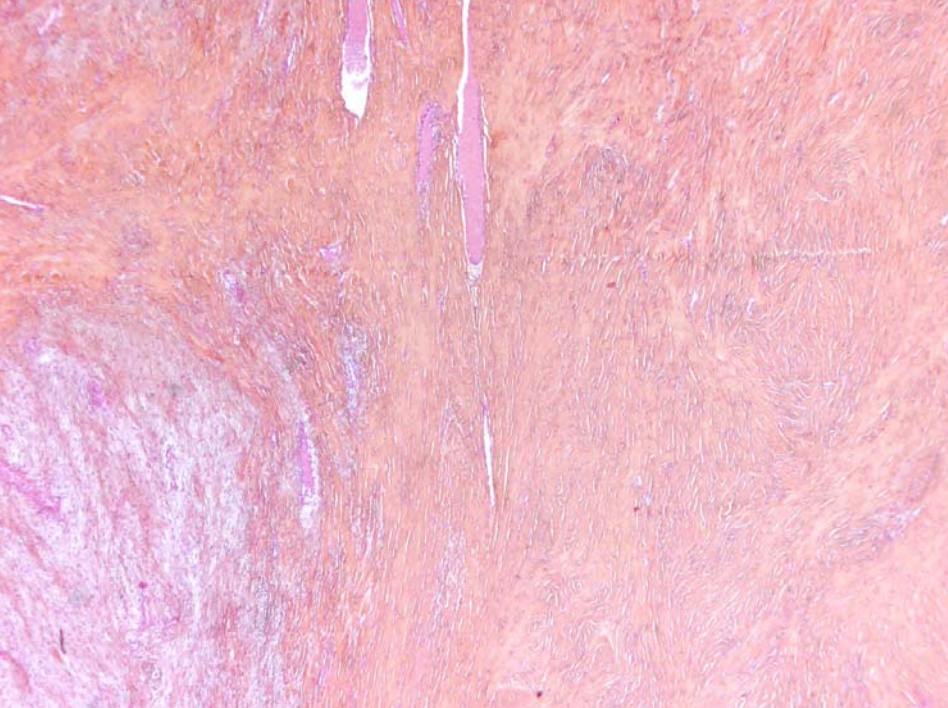
## **Cas 2: Corinne M...**



⌘ Proposition de prise en charge?

**Corinne M...**  
**MACRO**





## Cas 2: Corinne M...



- ⌘ Diagnostic final : sarcome fibromyxoïde de bas grade
- ⌘ Proposition:
  - ☑ reprise chirurgicale
  - ☑ irradiation complémentaire